



Smile Transformation:

Resolving Anterior Crossbite With Clear Aligners

Dr. Nasreen Nagani and Dr. Waqas Wahab
Consultant Orthodontist, Dento Correct
Clinic Lahore, Pakistan

Published: 08 May, 2024

Smile Transformation: Resolving Anterior Crossbite with Clear Aligners

Nagani N* and Wahab W

Consultant Orthodontist, Dento Correct Clinic Lahore, Pakistan

Article Info

Article History:

Received: 16 April, 2024

Accepted: 04 May, 2024

Published: 08 May, 2024

***Corresponding author:** Nagani N,
Consultant Orthodontist, Dento Correct
Clinic Lahore, Pakistan;
DOI: <https://doi.org/10.36266/JODHR/174>

Abstract

Clear aligner therapy has become a well-regarded orthodontic procedure recognized for its cosmetic appeal and comfort, particularly among adult patients. This case report delves into the clear aligner treatment administered to an adult patient presenting with an anterior crossbite and crowding. The treatment involved a non-extraction approach, utilizing arch expansion and interproximal reduction (IPR). A total of 22 sets of clear aligners were provided, with a recommended wear time of 22 hours per day for 10 days, spanning an eight-month period. As a result, this case study emphasizes the efficacy of clear aligners in orthodontic treatment for addressing anterior crossbite issues. The discreet design of these aligners not only promotes improved periodontal health but also enhances patient acceptance.

Key Words: Anterior Crossbite, Esthetic Treatment, Clear Aligners

Copyright: © 2024 Nagani N, et al. This is an open-access article distributed under the terms of the Creative Commons Attribution License, which permits unrestricted use, distribution, and reproduction in any medium, provided the original author and source are credited.

Introduction

Correcting anterior crossbite is crucial for both aesthetic and functional reasons, requiring early intervention to facilitate proper occlusal development [1]. Moyer defines anterior crossbite as the abnormal axial alignment of one or more maxillary teeth, characterized by the lingual positioning of the upper anterior teeth relative to the lower ones or a reverse overjet [2,3].

The prevalence of anterior dental crossbite globally is estimated to be between 4% and 5% [4]. Various factors contribute to its development, such as trauma, supernumerary teeth, crowding, lip biting, retention of primary teeth beyond their natural time, necrotic primary tooth or root, delayed shedding of primary incisors, and the presence of odontomas [5,6].

Anterior crossbite can be dental, skeletal or functional, either individually or in combination. Dental crossbite may develop due to changes in tooth position, while skeletal is characterized by a basal bone mismatch in the sagittal plane. Functional crossbite, also known as pseudo-Class III, occurs when occlusal interferences lead to mandibular displacement upon closure [7].

A variety of treatment options exist, both orthodontic and non-orthodontic. Non orthodontic approaches comprise the use of tongue blades, composite inclined planes, reversed stainless steel crowns, unusually thick restorations, and extractions with subsequent prosthetic replacement in older individuals. Less frequently utilized alternatives encompass the selective reshaping of teeth, surgical adjustment of tooth position, and segmental osteotomy of the affected teeth. Orthodontic solutions encompass a variety of removable acrylic appliances and fixed appliances featuring lingual springs and expansion screws. Each option presents its own advantages and disadvantages [8].

In 1946, Kesling introduced the concept of employing a sequence of thermoplastic positioners for teeth movement. Clear aligner technology was later introduced by Align Technology in 1997. Since then, it has undergone significant advancements, enabling the correction of many irregularities that were not feasible with earlier appliances. Essentially, these appliances utilize a series of clear aligners to gradually shift teeth, typically by 0.25–0.3 mm per aligner. These aligners are worn for 7 to 14 days per tray, depending on the manufacturer's guidelines. Initially, they were crafted on stone casts, but now thermoforming and three-dimensional printing techniques are commonly employed, providing manufacturers with enhanced control over tooth movements [9].

This case study details the utilization of clear aligners to correct anterior crossbite in an adult patient. It documents the treatment journey, highlighting any advancements made and the final results of this specific orthodontic approach in addressing the identified issue. The aim of the report is to offer understanding into the treatment strategy, the use of clear aligners, the patient's reaction to the treatment, any obstacles encountered during the procedure, and primarily, the success of the treatment in rectifying the malocclusion.

Case Report

A 17-year-old female patient visited our dental office with complaints of an anterior crossbite, misalignment, and crooked upper and lower teeth. She had no significant medical history or family dental problems. During the external examination, we

observed a mesencephalic head shape, mesioproscopic face shape, symmetrical frontal appearance, balanced profile, medium-sized nose, and competent lips (see Figure 1). The interlabial was within the normal range. The temporomandibular joint examination revealed no symptoms or concerns.

During the assessment of the smile, we noticed that there was a sufficient display of incisors, although the alignment of the teeth was not ideal. The curvature of the smile arc was nearly flat with that of the lower lip. Upon intraoral examination, we identified a class III malocclusion with satisfactory oral hygiene and average periodontal condition. Both molars exhibited class III relationships, while the canines were class I on both sides, and the incisors showed a class III relationship with a reverse overjet of -2 mm. The overbite was within normal limits at 3 mm. The upper midline was aligned, while the lower midline deviated 1.5 mm to the left.

Cast analysis revealed crowding of 5mm in the upper arch and 3mm in the lower arch. A panoramic radiograph confirmed the absence of cavities, root resorption, or any dental irregularities, indicating a healthy periodontal condition. Cephalometric analysis revealed a skeletal Class I relationship and a normodivergent facial pattern, characterized by an acute nasolabial angle.

Treatment objectives

The primary goal of the orthodontic treatment involved the correction of anterior crossbite esthetically through the use of clear aligners without using elastic button technique (EBT). Additional objectives included leveling, alignment and decrowding of both the arches and correction of midline through arch expansion and interproximal reduction (IPR).

Treatment options

We discussed different treatment options with the patient, considering the following:
Initially, we proposed traditional braces for orthodontic treatment, but the patient opted against this choice, preferring a more visually attractive appliance.
As an alternative, we suggested the use of clear aligners, which aligned with the patient's preference for a solution that is aesthetically pleasing.

Treatment procedure

After completing the examination and history-taking process, we proceeded to capture intraoral and extraoral photographs, as well as intraoral scans using a specialized scanner. These records were then forwarded to the ClearPath facility to create a personalized treatment plan.
The panoramic X-ray affirmed the presence of ample bone structure and indicated average oral hygiene, meeting the necessary criteria for orthodontic treatment. No further dental procedures

were deemed necessary, making the case suitable for clear aligner treatment.
Following the submission of records, a 3D treatment plan consisting of 22 stages in both arches was formulated. The approach involved non-extraction, incorporating arch expansion and interproximal reduction (IPR). A treatment simulation (see figure: 2) was presented to the patient for review, and upon her satisfaction, approval was granted.
Within 7 days of submitting the records, we discussed the treatment plan with the patient. She expressed high satisfaction with the proposed approach, and no adjustments were deemed necessary. A total treatment duration of eight months was recommended and promptly accepted by the patient. Subsequently, treatment commenced shortly thereafter.

IPR Technique

Interproximal reduction (IPR) is a method involving the precise removal of a thin layer of enamel between adjacent teeth to alleviate crowding [10]. Various techniques for IPR exist, such as the use of burs, discs, and abrasive strips [11]. In this particular investigation, thin diamond-coated double-sided abrasive strips were employed for IPR. The procedure was carefully measured using an IPR gauge, and afterward, topical fluoride was applied to prevent any potential adverse effects.

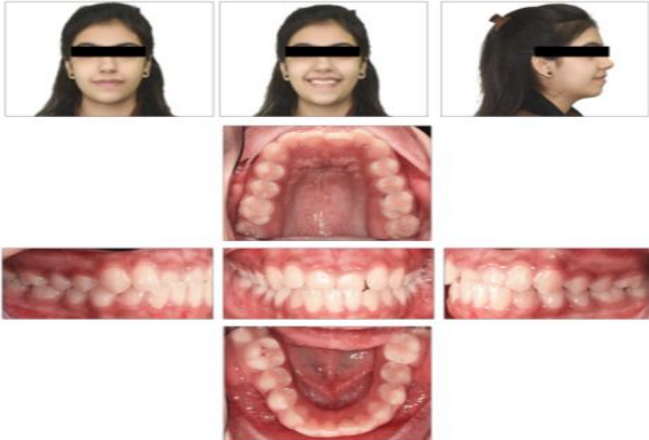

Figure-1: Pre-Treatment; Extraoral & Intraoral Photographs.

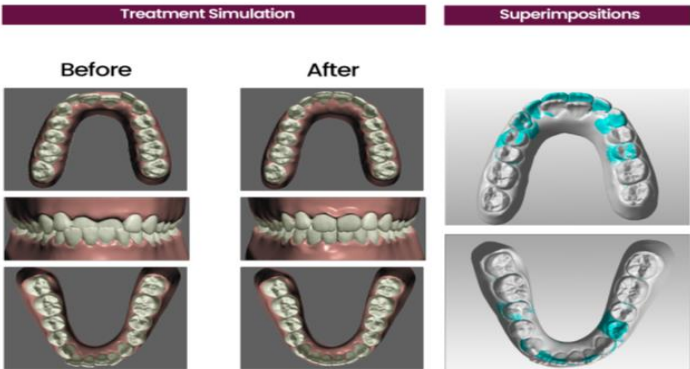


Figure-2: 3D Treatment Plan (A) Before & After, (B) Superimpositions.

Treatment progress

IPR of 0.7mm was performed between the upper left canine and first premolar before aligner number nine. IPR at six contact points was planned in the lower arch, scheduled across two visits. A 0.6mm IPR was conducted between the lower central and lateral incisors bilaterally before aligner twelve. An IPR of 0.6mm was done between lower central incisors at the same stage. Subsequently, 0.6mm IPR was done between the lower lateral incisors and canines bilaterally, while 0.7mm was performed between the lower right canine and first premolar before aligner eighteen. The patient then received successive sets of aligners and underwent evaluations of periodontal health and aligner tracking every three months, consistently demonstrating satisfactory results due to commendable compliance.

Treatment Diagram

Figure-3: *lpr* Form.

Figure-4: Movement Record Form.

Figure 5: Post Treatment Records; Extra Oral And Intra Oral Photographs.

The entire treatment spanned 8 months, during which each aligner was worn for a substantial 22 hours daily and replaced every 10 days. By the end of this period, successful resolution of crowding

and anterior crossbite was achieved. This led to the attainment of an ideal overjet and overbite, ensuring proper alignment and bite function (see figure: 5).

Furthermore, the treatment resulted in the harmonious alignment of both the maxillary and mandibular arches, enhancing both the esthetic and functional aspects of the patient's smile. Notably, meticulous attention to periodontal health was maintained throughout the treatment, with no signs of gum recession or the emergence of periodontal pockets, thus safeguarding the overall oral health and well-being of the patient.

Discussion

This study aimed to showcase a successful case of anterior crossbite treatment using clear aligners with a non-extraction approach. Given the perceived limitations of alternative methods, clear aligners emerge as a comfortable and well-tolerated option for adult patients seeking correction of anterior crossbite. These aligners allow patients to engage in their daily activities without aesthetic restrictions and facilitate optimal oral hygiene maintenance through easy removal and rigorous care. Furthermore, they help preserve periodontal health and prevent dental decalcification during orthodontic treatment [12,13].

In this specific case, involving anterior crossbite, moderate crowding, and misalignment, clear aligners were effectively utilized over an 8-month period. Arch expansion and interproximal reduction (IPR) were performed to alleviate crowding and correct the crossbite. The midline correction was also achieved using a total of 22 upper and lower aligners. Despite being presented with alternative treatment options, the patient opted for clear aligners due to their discreetness, hygienic benefits, and comfort. Clear aligners offer a unique treatment approach for adult orthodontic patients, addressing aesthetic concerns, promoting oral hygiene, and addressing metal allergy issues while maintaining a treatment duration comparable to traditional fixed appliances [14].

In the realm of clear aligner treatment, ensuring patient compliance is paramount. Patient education serves as a crucial motivational tool, influencing appliance acceptance and compliance. In this case, the patient's active involvement and communication with their clinician significantly contributed to the treatment's success. The patient engaged with the 3D setup software, which visually depicted the anticipated tooth movement and progress throughout the treatment, demonstrating the software's value as an educational tool for patients [15,16].

However, it's important to acknowledge the limitations of the clear aligner system [17]. It may demonstrate less predictability in cases involving severe rotations, complex extrusions, or significant translations, potentially necessitating additional treatment modalities. Despite potentially higher laboratory fees compared to conventional appliances, the virtual treatment setup, user-friendly interface, and high patient acceptance often justify the additional

cost [14]. This setup aids in diagnosis and serves as an educational tool for patients. Moreover, patient cooperation remains crucial for treatment success, and in this case, it was excellent due to the patient's enthusiasm for the process.

Conclusion

This case study underscores the effectiveness of clear aligners in orthodontic treatment for correcting anterior crossbite. The discreet design of these aligners not only supports periodontal health but also enhances patient acceptance. Moreover, the precise management of orthodontic movements, combined with minimal risk of anchorage loss, makes it an appealing option for clinicians in addressing such malocclusions.

Consent & Conflict Of Interest

A written consent form was signed from the patient for use of the dental records for publications & social media marketing. Also, there is no conflict of interest with this paper.

References

1. Frey CJ, Full CA. Correction of combined anterior and posterior crossbites in the primary dentition with fixed appliances: Case report. *Pediatr Dent*. 1988; 10: 105-107.
2. Moyers RE. *Hand Book of Orthodontics*. 3rd ed. Chicago: Year Book Medical Publishers. 1988.
3. Spear FM. The esthetic correction of anterior dental mal-alignment conventional vs. instant (restorative) orthodontics. *J Calif Dent Assoc*. 2004; 32: 133-141.
4. Tsai HH. Components of anterior crossbite in the primary dentition. *ASDC J Dent Child*. 2001; 68: 27-32.
5. Olsen CB. Anterior crossbite correction in uncooperative or disabled children. Case reports. *Aust Dent J*. 1996; 41: 304-309.
6. Major PW, Glover K. Treatment of anterior cross-bites in the early mixed dentition. *J Can Dent Assoc*. 1992; 58.
7. Wiedel A, Bondemark L. Fixed versus removable orthodontic appliances to correct anterior cross bite in the mixed dentition: a randomized controlled trial. *Eur J Orthod*. 2015; 37: 123-127.
8. Post AC, Balaban B, Ackerson HA, Vaught RD. Correction of anterior cross-bite using segmental osteotomies and a fixed splint. *J Prosthet Dent*. 1980; 43: 516-520.
9. Kuo E, Miller RJ. Automated custom-manufacturing technology in orthodontics. *Am J Orthod Dentofacial Orthop*. 2003; 123: 578-581.
10. Meredith L, Li M, Cannon RD, Farella M. Interproximal reduction in orthodontics: why, where, how much to remove? *Aust Orthod J*. 2017; 33: 150-157.
11. Lapenaite E, Lopatiene K. Interproximal enamel reduction as a part of orthodontic treatment. *Stomatologija*. 2014; 16: 19-24.
12. Wiedel AP, Norlund A, Petren S, Bondemark L. A cost minimization analysis of early correction of anterior crossbite: a randomized controlled trial. *Eur J Orthod*. 2016; 38: 140-145.
13. Li X, Ren C, Wang Z, Zhao P, Wang H, Bai Y. Changes in force associated with the amount of aligner activation and lingual bodily movement of the maxillary central incisor. *Korean J Orthod*. 2016; 46: 65-72.

14. Boyd RL, Miller RS, Vlaskalic V. The Invisalign system in adult orthodontics: mild crowding and space closure cases. J Clin Orthod. 2020; 34: 203-213.
15. Serogl HG, Klages U. A Zentner Pain and discomfort during orthodontic treatment: causative factors and effects on compliance. Am J Orthod Dentofacial Orthop. 1998; 114: 684-691.
16. Harris K, Ojima K, Dan C, Upadhyay M, Alshehri A, Kuo CL, et al. Evaluation of open bite closure using clear aligners: a retrospective study. Progress in Orthodontics. 2020; 21: 1-9.
17. Rask H, English JD, Colville C, Kasper FK, Gallerano R, Jacob HB. Cephalometric evaluation of changes in vertical dimension and molar position in adult non-extraction treatment with clear aligners and traditional fixed appliances. Dental Press J Orthod. 2021; 26: 1-25.